


HAAD exam 09 April 2015

1. Photo of an ECG as below: Ask for the diagnosis

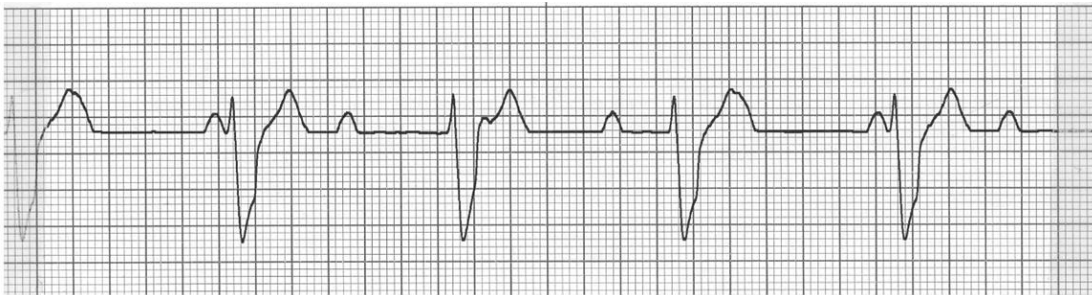


Answer was ventricular tachycardia

2-Photo of a patient with same ECG as above. Says patient was brought to the emergency room and is unresponsive. Asks what is the appropriate next step?

Cardioversion

3-ECG Like that below asking for diagnosis:



rd degree heart block3Answer is

4- long case of typical RHUMATIC ARTHRITIS ...then tell you the patient was treated with ketoprofen for 6 month and during the last 3month chloroquine was added .Then the patient had knee pain and minimal fluid and there was problem in his hand (weakness or pain ?) .Investigations shows that his CRP and ESR values are doubled from the one was done one month earlier .His renal and kidney functions are normalWhat to do next?

a-Stop Ketoprofen and give Prednison

b-Stop chloroquine and give methotrexate

c-Add methotrexate

d-Add Abatacept

5- Case presentation of ,Hyperpigmentation , High ACTH, Abdominal stria ,Face acne, round face , nocturnal polyuria , polydipsia. what is the cause ?

-Adrenal adenoma

-Adrenal carcinoma

-Pituitary adenoma

-MEN type 2 syndrome

6-Female coming with lower abdominal pain ,tenderness and dyspareunia ,examination show nodule on the posterior fornix of vagina(AS IT IS ENDOMETRIC TISSUE OF ENDOMETRIOSIS IMPACTED IN VAGINA). What is the next step?

-Laparoscopy

علشان نشيلها بيه

-Vaginal US

Laparotomy

7-what is most serious side effect of haloperidol / antipsychotic?

Neuroleptic Malignant Syndrome

8-73 year old lady has vaginal bleeding ,has done total abdominal hysterectomy and bilateral salpingo-oophorectomy. Vagina show petechial Hamorrhage...what is the ttt?

-Estrogen

Progesterone

Estrogen +Progesterone

9-Patient admitted for treatment of infection was given streptomycin and gentamycin ,his illness improved but checking creatinin level is elevated (was normal on admission) what is the cause:

-proliferative GN

-Gentamycin induced

10- Old man given augmentin, after one week presents with diarrhea and bleeding per rectum. What is diagnosis?

Pseudomembranous colitis

Crohns

11-A very long case about SLE ,had bleeding ,blue ecchymotic patches on his hands and feet and so many investigations asking which test to confirm diagnosis? Investigation shows increase in cardiolipin antibodies. What test can you do to confirm this?

-Low C3 and C4

-Lupus anticoagulant

12-child has varicella ,mother is pregnant and doesn't remember if she was vaccinated or not .next step?

Check Varicella IgG

Check IgM

13-Patient is coming to you as heard his friend has AAA. Ask you the method of screening of Abdominal Aortic Aneurysm → by **Abdominal US**

14- Case of Diagnosis of **Acute pancreatitis** (Diabetic with epigastric pain radiate to the back ,no jaundice)

15-Diagnosis of **Testicular Feminization Syndrome**(female with primary amenorrhea , minimal pubic hair and breast ,normal ext genitalia ,bilateral solid inguinal masses)

16-**Radial nerve injury** Saturday night paralysis

17-child 6 month old developed pansystolic murmur(wasn't there after birth) ,heart sounds are normal. Diagnosis – ASD -**VSD** -PDA –Coarctation of the aorta

18- patient coming with haematemesis ,he vomited blood at home and at ER, has BLPr while sitting 80/60 while lying flat 110/70 what to give him

-**Nacl saline 1000 ml bolus**

-Oxterotide 50µ

19- Case of farmer has pain in the ankle joint, hot, tender Diagnosis **Septic arthritis**

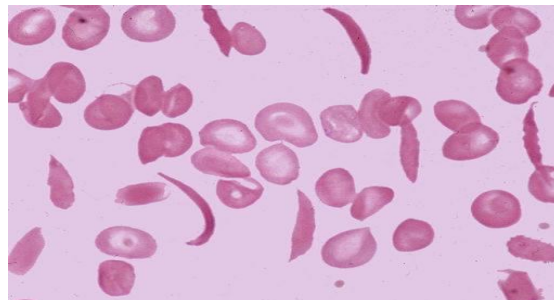
20- Case of scarlet fever ; circumoral pallor what is next?

-hospitalization and IV penicillin

-**Throat culture and oral penicillin**

21-Cardiology case and in the middle of the case mentioned sudden death history in the family ask the diagnosis = **Hypertrophic cardiomyopathy**.

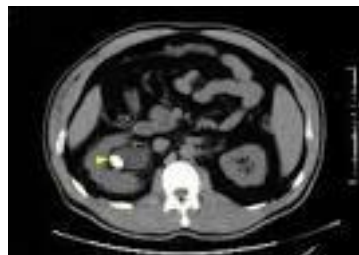22- Case of **Aortic Dissection** describing the chest pain in the inter-scapular region and brought ECG ask the diagnosis



23-**SCA** PHOTO

24-Case of **Testicular torsion** asking Diagnosis(sudden sever pain in the testis+high riding testis +intact cremastic reflexes)

25-Trauma to abdomen with broken ribs 11 and 12 .What is the injured organ ? kidney , **spleen**



26-X-ray and CT photo asking the diagnosis **Hyperparathyroidism**

27- 4 year old child developed leg pain unable to bear weight, has a mild fever, ESR =50 and CRP =200.Ask Diagnosis

- Slipped Capital Femoral
- Avascular necrosis
- slipped arthroplastic joint

-Septic arthritis

28- Female patient had vaginal delivery in 18 hours of 2900grams, she came to you 30 minutes earlier in the ER . she had vaginal bleeding after delivery and continued .Her past history Hb 9 mg/dl in the 3rd trimester .What is the cause of post partum haemorrhage?

-Atony

- Vaginal tear
- retained placenta

29-case **of iron deficiency anemia** (Low Hb,Low MCV ,High RDW)

30-case of baby fed on cow milk has itching and excoriation in the cubital fossa ask next step **give corticosteroid.**

32-stab wound in the chest, muffled/distant heart sounds(cardiac tamponade) ask next step?

-Trans thoracic Echo

- Trans Esophageal Echo

33-Case of post operative hypotension+shifting dullness. asking next step:

-0.9% Nacl bolus dose

- Paracentesis
- Laparotomy

34-Case of Horner syndrome (ptosis ,myosis,anhidrosis) ask next step in investigation → **Chest X ray** to check for pancost tumor a common association with Horner.

35-61 year old man has weak stream of urine, his PROSTATIC SPECIFIC AG last year was 8.9 then it 's 8.8 this year

prostate is smooth and enlarged .what to do next:

- Trans-rectal guided biopsy
- Trans urethral biopsy
- give finasterid

-give tamsulosin

36-11 year old Child with asthma on salbutamole inhaler 200mg he wants some better drug:

- Ipratropium
- Thyophylline

- **Budesonide inhalation(Cortisol)**

-Salmeterol

37-Case of **Willm's tumor** (child with abdominal mass and haematuria)

38-case of watery diarrhea ,pain, tenderness in the right lower of the abdomen, ulcer in the terminal ileum ask the diagnosis :

-**Crohn's disease**

-Appenicitis

-Ulcerative colitis

39-Case of **orbital cellulitis** ask diagnosis (boy coming with eye laceration ,pain ,proptosis,limitation of movement, normal optic disc)

40-Epidemiology case of Juvenile Rheumatoid Arthritis ask how to collect cases

-From Discharge files of hospital

-From disease hotline services

- **Consultant pediatrics at end of each month**

41- 40 year old lady with mass 2cm firm mobile, not fixed to the skin ,not painful or tender ,in mammogram show calcification with spiking/speculation

Diagnosis ?

Fibroadenoma

Adenocarcinoma

42-Breast mass 2 cm below the nipple when you press it there is serous secretion from the nipple what is the diagnosis :

-Carcinoma in Situ

-**Intraductal Papilloma**

-Ductal Carcinoma

43- 17y old female with mobile non tender upper left quadrant breast mass .she is on OCP for menstrual irregularity next step

a-FNA

b-mammogram

c-**follow up after 3 months**

44-An old man with delirium ,10 years ago he had stroke and quadriplegia. When he wake up he didn't recognize the nurse or his sons and daughters. what is the diagnosis? **UTI (Acute Infection)**

45- Case of **Cauda Equina lesion** ask diagnosis (Paresthesia in perineum ,LL weakness ,Urine Incontinence)

46-Old woman presents with back pain, came from long journey and tried to lift her heavy bags and back pain started. what is next? **-Diclofenac**

47- Another case of hypotension ask what is next ? give **IV .09% NaCl bolus dose**

48-Case of Amenorrhea and weight loss ,low fsh and lh ,she is doing exercise. What is the cause of amenorrhea?

-Hypothalamic amenorrhea

49-Child of 6 month old, develop poor feeding, has bilateral chest wheeze, RR = 40 , his peripheral pulse in hands is very fast and you cant even count it, his pedal pulses are there but weak. There is no fever , capillary refill is 4-5, ,he has palpable liver border, ask diagnosis ?

-Bronchiolitis

-Supraventricular tachycardia

-Sepsis

-Fulminant Hepatitis

50--20 years old patient with cystic fibrosis has chest infection.What is the causative organism ?

-Pseudomonas aeruginosa

-staphylococcus aureus

51-50 year old lady coming to you ,she is taking ttt vit D, Ca and Alendronate..What is the disease

-Renal failure

-osteoporosis

-osteomalacia

52-child have croup *barking cough*what will be heard on auscultation:

-decrease air entry

Inspiratory stridor

53 -Child swallowed peanut , on auscultation : there is chest wheeze .What will be seen on x-ray

-atelectasis

-hyper inflation

54-

55-pregnant lady 26 weeks , she is RH -ve ,husband RH +ve , titre was 1:256 what is the next step :

-Give Anti-D to the mother

--Give Anti-D to the fetus

Blood transfusion to the Fetus

Cesarian section

56- Case of painless jaundice -gall bladder palpable , what is the cause ? **pancreatic carcinoma**

57-Case of disc prolapse ask when is the emergency referral to neurology?

-Failure to initiate micturition (retention)

-weak planter flexion

58-65year-old retired female security guard with chronic bronchitis comes with complains of something coming out of vagina. G4P2A2.Her last labour was prolonged with complication Examination shows uterus at level of introitus. What is most important risk factor in this patient?

- Age
- Parity
- Prolonged standing
- Chronic bronchitis
- **her last labour complication?**

59- middle age man , has had heart burn for a long time, has dysphagia to solid then become to fluid. On examination he is obese , his lab values show microcytic hypochromic anemia ,what to do next?

-Endoscopy with biopsy

-Endoscopy with dilatation

-Barium studies

60- Female patient, finds out that she gets tired when she is chewing, she has dysphagia to solids and prefers fluids. Diagnosis

-Sjogren syndrome

-Myasthenia Gravis

61-Photo of child with deviated Right eye deviated to right side

-patch left eye

-patch right eye

-assess visual acuity

-surgery

62-Multigravida female in labor come with 6cm dilated cervix after 3hr she become 7cm contraction every 6-7min fetus cephalo transeverse ,with no caput , no moulding, she has pervious vaginal delivery – what is the next step in management

-augmentation of labor with oxytocin

-Cesarian Section

63-Primigravida coming in labor with 3 cm dilation and 80% effacement, there is no uterine contraction ,next step with stable fetus:

-Oxytocin IV

-Methergin maleate IM

-CS

-PG vaginally

64-person his father died from cancer colon his brother has colon polyp. What tes should be done to decreases his risk of Colon cancer

-fecal occult blood test

-colonoscopy

65-**Agoraphobia** (man brings his wife coz of her fear to go outside or do shopping)

66-**Body dysmorphic disorder** (30 year old lady teacher comes to you because of problem with her eye lid. She is wearing glasses to hide the large lesion in her eye, when u examine her you find a 2 mm lesion in her lower eye lid.)

67-**Hpochondriasis** (patient insist he has a serious diease despite multiple hospital visits with confirmation of absence of the disease)

68-**social phobia** (patient fear to do seminar)

69-**Infantile autism**(child with no eye contact ,play with certain parts of the toy with repetitive movements)

70-Parents bring child to hospital, with broken teeth, bruising at different stages of healing:
child abuse

71-30 year old mentally retarded ,was recently emerged in the society now sitting in his room and close his door, he has urine and stool incontinence ,he was used to express his needs by certain voices now he prefer to be alone. What is the diagnosis?

-Physical abuse

-Major depression

72-A college student comes to u complain of having "Curse Words" in his mind and he can't get rid of it. What is this type of thinking?

-Obsessive

referential

-Delusionsional

73-What is the most sensitive test for breast mass ?

1-US

2-**FNA**

3-Mammography

4-Clinical exam

74- Patient with shifted trachea, tension pneumothorax management ... **Wide pore needle insertion**

75-case DIC –PT elevated-PTT elevated-INR elevated give him cryo- precipitate and fresh frozen plasma what you should give him

-heparin

platelet

76- Case of severe chest pain ,relieved after some time, ECG is normal: What to do next?

Stress ECG after one week.

77-Case of Antiphospholipid syndrome after labor developed chest pain ,tachycardia ,tachypnea. ask diagnosis? **Pulmonary Embolism**

78- lady was treated from pre-eclampsia with MgSo4 and developed dyspnea ,tachypnea, bilatreal crackles after labour . What is the diagnosis? **Pulmonary edema**

79-old patient complain of syncopal attacks without warning.He has ejection systolic murmur(AS) dorsalis pedis pulse is absent .He regains consciousness immediately. Ask diagnosis

1-**Vasovaga attack**

2-Arrythemia

80-Diabetic patient on metformin and many drug names and he has congestive Heart Failure ,obese.What is the drug contraindicated in this patient? **Thiazolidindiones**

81- Cardiac patient taking many drugs including Ca channel blocker(CCB) developed LL edema . what is the cause of edema ? **Amlodipin (CCB)**

82- Thyroid mass in the right lobe 2*2.5*1.5 cm ,surgery done and removed right lobe ,pathology show follicular carcinoma what is the next step?

a- Remove the Left side (total thyroidectomy) + Radio –iodine therapy

b-Total thyroidectomy + External Radiation

c-Radiation only

d- Radio-iodine only

83-Case of thyroid mention +ve antithyroglobulin antibodies .Diagnosis ? **Hashimoto thyroiditis**

84- Female patient with chronic cough ,hoarsness of voice and morning clearance of throat. What is the diagnosis? **GERD**

85-Case of lab results of **Vaccinated against HBV** (presence of the surface antibodies and absence of the surface antigen)

86- Cancer colon metastasize to ==> **liver**

87-Neurology case with weakness in the upper limb more than the lower limb,bladder function normal .**Central spine syndrome**

88-Case of low back pain increase with standing and walking and improve by sitting . **Spinal Stenosis syndrome**

89-Old age with hemiparesis on right side and aphasia , which vessel is occluded? **Left middle cerebral artery**

90-Adolescent with seizure at school is due to which drug withdrawal ? **Benzodiazepines**

91- Case of female on OCP complain of headache ,diplopia, photophobia ,and optic disc show papilloedma , relived after lumbar puncture .What is the diagnosis? **Idiopathic(benign) increase in intracranial tension**

92-Case of rupture of membranes next step==> **Sterile speculum examination and PH**

93-Case of pre-eclampsia BIPr 160/110 and mild proteinuria. What is the drug to give? **alpha methyl dopa**

94- Case of Alcohol withdrawal ttt **Chlodiazopoxide**

95-Infant of mother with gestational diabetes developed seizures after delivery.What is the cause? **Gestational Diabetes**. Other options were very strange names.

96-Pregnant 12 weeks developed bleeding ,absent heart sounds, abdominal examination show uterine level at 20 weeks, US show bilateral enlarged ovaries ? **Molar pregnancy**

97-patient with painful contraction coming and going but now no pain? **False labour pain**

98-Case of genital ulcer with clear discharge and dysparunia,inguinal lymphadenopathy .Diagnosis ? **Herpes genitalis**

99-middle age man with symptoms of pneumonia not toxic. Antibiotic choice? **Augmentin**

100-Antibiotic choice for breast abscess in lactating woman? **Flucloxacillin**

101- patient post menopausal with vaginal bleeding endometrial biopsy show endometrial thickness 10 mm .Biopsy show hyperplasia with atypia next step in management

-endometrial ablation

- **total abdominal hysterctiomy with BSO**

- D&C

102-Case of appendicular mass ==> **Analgesic and antibiotic**

103-Diagnosis of slipped capital femoral by ==> **X-ray**

104- newborn infant was born after CS developed tachypnea,dyspnea ,X ray show bilateral fluid in lobar fissures ==> **Transient Tachpnea of the Newborn (TTN)**

105- Case of **ASD** ==> wide fixed splitting of S2 ,rt ventricular hypertrophy and increased pulmonary vasculature.

106- Pregnant female in 2nd trimester developed dyspnea ,basal crepitations ,increased JVP,diastolic murmur in Apex ==> **Mitral Stenosis**.

107-Case of Glomerulonephritis .Urine will show ==> **RBCs cast**

108- girl with history of asthma come to you with chest wheeze and retraction.What to do next ?

-O2 and Salbutamole

-ABG

109-Scenario on patient treated with haloperidol then ask what is the most serious side effect of Antipsychotic drugs? **Neuroleptic Malignant Syndrome**

110- patient came in shock. best indicator of good resuscitation ==> **Urine Output >40ml/hr**

111- Case of lung nodule was 1 cm from 8 years now it is 2.5 cm CT suggest it has calcification and fat? next step **follow up(no further investigation)**

112-Old man with stroke ask investigation ? **CT**

113- Old woman came to doctor, without her children, clothes look tattered and torn, children refuse to follow her to hospital : **elderly neglect**

114- young man with right lower abdominal pain ,unremarkable mcBurney point very tender per-rectal examination. ask diagnosis

a-pelvic brim appendicitis

b-diverticulitis

c-mesenteric lymphadenitis

115-child with family history of chronic renal failure (his mother had kidney disease) .Ask diagnosis? **Polycystic Kidney disease**

116- Female patient ,she works in data entry , she spent the whole night yesterday with her friend in the office in typing .She complains of shoulder pain and numbness on her arms , phalen and talen test are -ve .What is the cause ?

-Tendonitis due to repeated use of keyboard

-Static state in her shoulders(lack of movement)

117- male complaining from pain on head extension not in head flexion there is diminished biceps reflex +shoulder pain

a-thoracic outlet syndrome

b-C6 radiculopathy

c-supraspinatus tendinitis

118-Old lady come with her daughter , she is telling that her mother become lazy with daytime sleeping ,crying and depressed .What to do next ? **TSH level**

119-Diabetic patient has tingling and numbness, burning sensation in his sole .What is the cause ? **Diabetic Neuropathy**

120- Old man with CAD risk of 1% only. He is 51 years old. What advise will you give to him to prevent CAD in next ten years.

I picked: exercise 30 mins daily